

Delayed treatment of paediatric supracondylar humerus fracture with neuro-vascular compromise



Mangala Bhargav Sunkara¹, Nishant N Gholap², Amar Vishal³, Dev Manohar⁴, Robin C Raju⁵

^{1,4,5}Resident, ²Assistant Professor, ³Professor and Head, Department of Orthopaedics and Traumatology, Konaseema Institute of Medical Sciences & Research Foundation, Chaitanya Nagar, Amalapuram, Andhra Pradesh, India. PIN 533201

Abstract

Introduction: Supracondylar humerus fractures are common in children (3% of all paediatric fractures). Type III fracture is associated with neuro-vascular compromise (10-20%) & the appropriate management was delayed due to various factors. Unavailability of vascular and orthopaedic surgeon both at one place at small health centre is one of them.

Case Report: 10-year-old girl was referred to our hospital with a painful left elbow with a history of high-energy trauma. On the first examination, the elbow was found to be swollen and a 4 cm linear surgical wound was observed on the antero-medial aspect of the left elbow, due to limited exposure of artery, done by vascular surgeon at one centre, with feeble distal pulse & painful finger movements were present. Patient presented 5 days later to our centre. We are presenting, the 4-month results of our patient, who got fixed with percutaneous Kirshner-wire after gentle traction and closed reduction.

Clinical discussion: Type III & IV modified Gartland supracondylar fractures are associated with compartment syndrome, neurovascular compromise and VIC. Care should be taken to reduce the fracture at an earliest & getting as anatomical a reduction as possible by orthopaedic surgeon and vascular surgeon should manage the brachial artery compromise in same sitting on an emergent basis.

Conclusion: Type III & IV modified Gartland supracondylar fractures associated with neuro vascular compromise should be sent to a centre where both orthopaedic and vascular surgeon are available for treatment of such type of fractures. Only vascular repair without addressing the fracture fixation is not advisable.

Keywords: Supracondylar fracture, Neuro-Vascular complication, percutaneous k-wire fixation, Volkmann's ischemic contracture

Access This Article

This is an open access article distributed under the terms of the Creative Commons Attribution-NonCommercial-ShareAlike 3.0 License, which allows others to remix, tweak, and build upon the work non-commercially, as long as the author is credited and the new creations are licensed under the identical terms.

Copyright (c) 2024 International Journal Of Medical Case Report



This work is licensed under a Creative Commons Attribution-NonCommercial 4.0 International License

Access this Journal Online

Quick Response Code



Website: www.ijomcr.net

Email: ijomcr@gmail.com

Corresponding Authors:-

Dr. Nishant N Gholap

Address Flat No 309 Godavari Block Dr's Quarter, KIMS Amalapuram, Andhara Pradesh India

Contact 8975760296

Email: nishantngholap@gmail.com

Supracondylar fractures of the distal humerus are the most common elbow fracture in children and account for approximately 3% of all paediatric fractures. It is most common in 5–7-year of age group. 98% are of extension type and flexion type is rare. 5-10% fractures are associated with fracture of distal radius. Modified Gartland classification is most commonly used classification. Wilkins et al later modified it into type I, type II A and type II B, type III and type IV.¹ Supracondylar fractures of the humerus with neuro-vascular compromise are observed in modified Gartland type III and IV (10-15% nerve injury, 10-20% vascular injury) fractures. Anterior interosseous nerve is most common nerve injured in extension type & ulnar nerve damage is most common in flexion type. Obese patients have high incidence of pre and post operative nerve palsy. Recovery rate is 100% for radial nerve, 88% for median nerve and 25% for ulnar nerve after damage.

Fracture with non-perfused limb is an emergency and if not treated early then compartment syndrome leading to Volkmann's ischemic contracture (VIC) are the common complications.² Incidence of compartment syndrome is 0.1-0.3% and is more commonly seen with association of both bone fractures, floating elbow and distal end radius fractures. If pulse is not palpable and extremity is cold then urgent fixation of fracture and exploration of brachial artery is to be done in same sitting & if after reduction the circulation is not restored in the hand. Percutaneous pinning is most common method of fixation of these fractures. Pin related complications like local irritation, proximal migration and infection occurs in less than 5% of patient. Ideal pin configuration is still controversial. With medial and lateral pinning, the union rate is same but higher rate of nerve injury seen in case of medial pinning. If only lateral pinning is to be used, then 2 k wires are passed from lateral side with minimum 2mm distance from each other and should have bi-cortical hold. 2-3 lateral pins are sufficient and medial pins to be used if fracture is unstable (type III & IV). For type III & IV fracture fixation, c-arm to be rotated rather than the arm. Crescent sign is used to check for rotation element and Baumann angle is used as guide for correcting coronal tilt. 10% cases require open reduction and the indications are like irreducible fracture, open fractures and neurovascular compromise fractures. For neurovascular

compromise, direct anterior approach is used most commonly.³

Technique for close reduction is traction in extension, correct the medial & lateral translation and internal rotation and confirm on c-arm and then flexion to be done in pronation to close the posterior and medial periosteum hinge. In rare flexion type of injury, reduction to be done in extension and k-wire to be passed in extension. If reduction is not possible, then open reduction is to be done by posterior approach.⁴ 2 lateral pins to be passed in divergent manner and should not cross at the fracture site. After pinning, we have to check the stability of fracture by Varus-valgus and rotational stress & carrying angle. to be checked compare to opposite side. Depending upon the stability, third wire to be passed either laterally or medially. Post op well-padded plaster slab to be given at elbow in 60 degrees of flexion to maintain space at antecubital fossa. After 1 week, once the oedema subsides, above elbow slab to be given at 90 degrees of flexion. Slab to be removed at 1 month time and k wire to be removed at 6 weeks' time, once callus formation is seen on x-ray. Range of movement to be started at 1 month time after plaster removal. Compartment syndrome leading to VIC is common complication in untreated type III and IV fractures.⁵

In case of Vascular compromise anterior approach is to be used by dissecting between plane of biceps, brachialis and brachioradialis muscle. Exploration of brachial artery to be done and direct repair or venous graft to be used for repair. Cubitus varus is most common deformity and close wedge osteotomy is advised for correction. Hyper flexion to be corrected by fixing the fracture in little flexion. The treatment protocol for these fractures is still not fully standardized. Studies on such paediatric upper extremity fracture cases are limited in the literature. It is important to determine the pre-operative and post-operative complications of these fractures that occur with high energy.⁶

In this case report, the results of delayed presentation of supracondylar humerus fracture associated with neuro-vascular deficits treated partially for vascular compromise without fixation of supracondylar fracture TYPE III at same sitting at a private hospital and left neglected for 5 days before presenting to us with feeble radial pulse and

little movement at fingers were evaluated & presented.

CASE REPORT

A 10-year-old girl was referred to our hospital (5 days post trauma) with a history of road traffic accident and complaining of pain, swelling at left elbow. Initially Patient was taken to local hospital with no distal pulse & finger movements, referred her immediately to vascular surgeon after colour Doppler study. Vascular injury got addressed & referred her back to previous hospital (after 5 days) for fracture fixation who referred her to our institute. On our first examination, it was observed that the elbow was swollen and there was a 4 cm linear surgical wound on the antero-medial surface of the left elbow & on neurovascular examination, distal pulses were feeble with flicker of movements in the fingers were seen. Radiographs showed us isolated supracondylar humerus fracture, extension type-III Gartland.

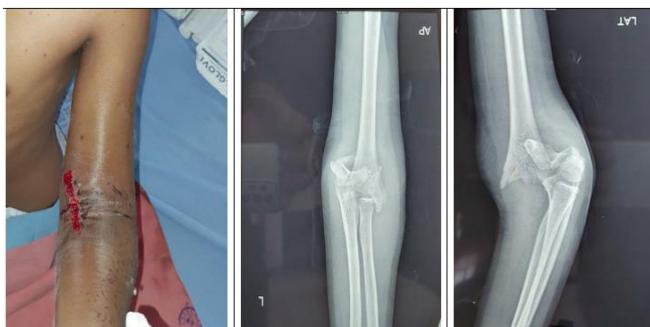

Fig. 1. Clinical image & Anteroposterior & lateral x-rays views showing supra-condylar fracture.

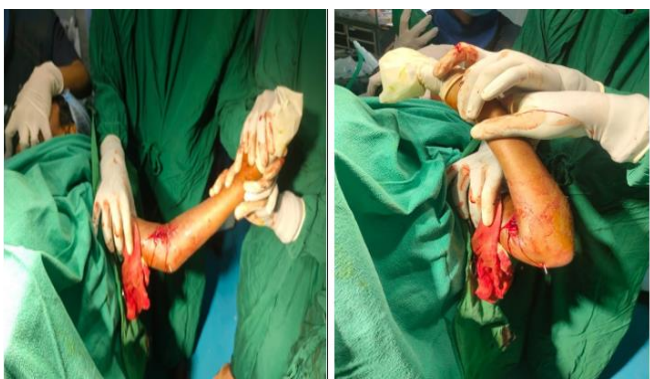

Fig. 2. Intraoperative clinical imaging of elbow

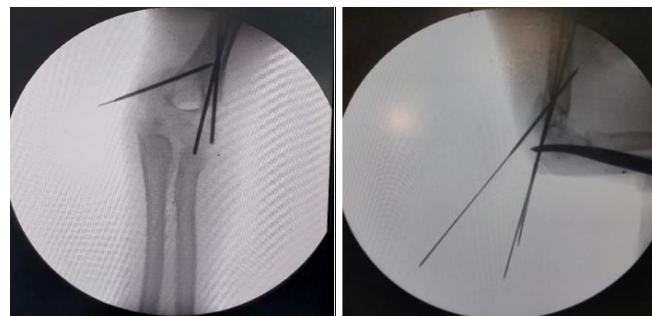


Fig. 3. Intraoperative X-ray imaging of elbow

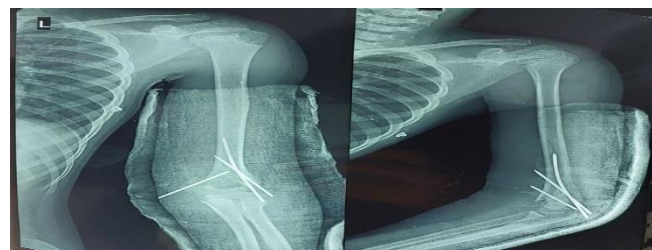

Fig. 4. Immediate Post-operative X-Ray.

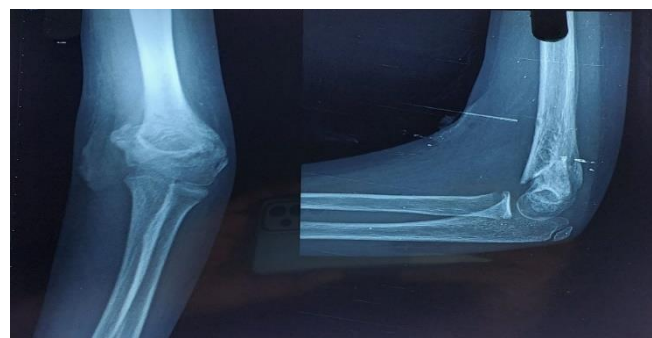

Fig. 5. Post-op x-ray images after removal of k wires

After the preoperative preparations, the patient underwent closed reduction of the fracture on an emergent basis. With application of continuous gentle traction, closed reduction was achieved & carefully 2 lateral and 1 medial Kirschner wires were pinned and checked by fluoroscopy. A long arm splint applied to the patient post-operatively in 40° flexion. After fracture reduction & stabilization, the swelling subsided gradually in 5 days. Surgical wound healing was satisfactory. The patient was discharged after 5 days & called for regular follow-ups. After 4 weeks, the Kirshner wires & splint was removed.

Our patient's elbow motion was initially limited with fixed flexion deformity i.e. 50° with further flexion up to 90° with Volkmann's sign positive for which regular physio-therapy was given with which elbow range of motion improved to 20° of fixed flexion deformity with further flexion of 100°. At four-months follow up visit, patient's

condition improved with clinical findings as follows .

| Clinical Findings | Outcome |
|---|-----------|
| Sensations of the hand | Intact |
| Power of biceps | Grade 4 |
| Power of triceps | Grade 5 |
| Wrist flexion | Grade 5 |
| Metacarpophalangeal joint Flexion | Grade 4+, |
| Extension | Grade 3 |
| Power at PIP & DIP joints in flexion & extension both | Grade 4+ |
| Both palmar & dorsal interossei | Grade 3+ |
| Volkmann sign positive and mild grade of VIC seen and radial artery found to be palpable with normal magnitude. | |

Table 1 :- Clinical Findings at 4 months follow up visit.

Patient is doing normal functional activity. However, she is finding weight lifting difficult, due to fixed length phenomenon.

DISCUSSION

Treatment of such cases should be done as early as possible to prevent the development of Volkmann's ischemic contractures & reduced range of motion in the joint where initial orthopaedic treatment was delayed. Management of pediatric supra-condylar humerus fracture always needs to be done on an urgent basis as there is significant association between delay in treatment & increased chances of neurovascular compromise and decreased range of motion.⁷ A good pre-operative examination is mandatory, as the risk of nerve injury from a supracondylar humerus fracture is 3 % after surgery. In such fractures, operative management usually begins with an attempt at close reduction. However, repetitive attempts at closed reduction can cause neuropraxia and joint stiffness, especially when a fracture was displaced completely. Therefore, open reduction is recommended in such cases. In our case, we were able to achieve closed reduction with gentle sustained traction, which was fixed with percutaneous Kirschner wires.⁸

When medial and lateral pinning techniques were compared, both have similar functional and radiological results and have almost similar biomechanical stability. Fixation with K-wires is a reliable method for unstable supracondylar

fractures and medial-lateral three-pin fixation is better than two-pin fixation. In our case, after fracture reduction, fixation was done with 2 lateral and 1 medial Kirshner wires. In the treatment, non-displaced or Gartland type 1 fracture can be treated with long arm cast or splint. However, it is widely accepted that type 3 and 4 fractures to be managed surgically, the open approach has been associated with a high rate of complications such as stiffness or myositis ossificans.⁹

However, recent studies have shown a lower incidence of complications compared with closed reduction and no difference in terms of loss of motion, infection, malunion, or subsequent surgery. In our case, Kirshner wires & splint were removed after four weeks; it was observed that the reduction was not entirely anatomical but some amount of rotational malalignment persisted due to huge tissue oedema as is evident in the clinical pictures.¹⁰ The fixed length phenomenon of flexors tendons was treated by above elbow cast followed by serial wedging on dorsum of wrist to stretch the flexor tendons & was done on OPD basis and patient recovered almost completely except with minimal weakness.

CONCLUSION

There is not much information in the literature about the delayed supracondylar humerus fractures fixation post vascular repair. Regarding manipulation of such fracture after vascular repair, there is always a danger of injuring the vascular structures once again with traction & manipulation. In our case, we did gentle, guarded gradual manipulation under C-ARM imaging with gentle traction and fixed elbow in semi-flexed position, stabilized with Kirschner wires, later elbow was mobilized at the earliest. Patients with supracondylar fracture with vascular deficits need urgent treatment, and to complete the job, the patient must be referred to a centre where both vascular and orthopaedic surgeons are available to avoid further complications. In any case, the fracture needs to be fixed first & then vascular repair is to be done immediately in the same sitting, if it is compromised

Conflict of interest

None

Source of Funding

None

REFERENCE

1. Wilkins KE: The operative management of supracondylar fractures, Ortho p Clin North Am 21:269, 1990.
2. Armstrong DG, MacNeille R, Lehman EB, Hennrikus WL. Compartment Syndrome in Children With a Supracondylar Fracture: Not Everyone has Risk Factors. J Orthop Trauma. 2021;35(8):e298-e303. doi:10.1097/BOT.0000000000002030
3. Aksakal M, Ermutlu C, Sarisözen B, Akesen B. Approach to supracondylar humerus fractures with neurovascular compromise in children. Acta Orthop Traumatol Turc. 2013;47(4):244-249. doi:10.3944/aott.2013.3012
4. Karagoz B, Kibar B, Oto O, Malkoc FE. Comparison of lateral, medial, and posterior approaches in the surgical treatment of pediatric supracondylar humerus fractures. North Clin Istanbul. 2023;10(2):255-262. Published 2023 Apr 14. doi:10.14744/nci.2021.09475
5. Preis J. Volkmannova kontraktura a suprakondylická zlomenina humeru u dětí [Volkmann's contracture and supracondylar fractures of the humerus in children]. Rozhl Chir. 2000;79(8):357-363.
6. Moore TJ, Watson T, Green SA, Garland DE, Chandler RW. Complications of surgically treated supracondylar fractures of the femur. J Trauma. 1987;27(4):402-406. doi:10.1097/00005373-198704000-00010
7. Kumar V, Singh A. Fracture Supracondylar Humerus: A Review. J Clin Diagn Res. 2016;10(12):RE01-RE06. doi:10.7860/JCDR/2016/21647.8942
8. Clancey GJ. Percutaneous Kirschner-wire fixation of Colles fractures. A prospective study of thirty cases. J Bone Joint Surg Am. 1984;66(7):1008-1014.
9. Vaquero-Picado A, González-Morán G, Moraleda L. Management of supracondylar fractures of the humerus in children. EFORT Open Rev. 2018;3(10):526-540. Published 2018 Oct 1. doi:10.1302/2058-5241.3.170049
10. Symons S, Persad R, Paterson M. The removal of percutaneous Kirschner wires used in the stabilisation of fractures in children. Acta Orthop Belg. 2005;71(1):88-90.

Author Contribution:- MS-Concept and design, NG manuscript preparation, AV revision of manuscript, DM RR review of manuscript.

How To Cite This Article

Mangala B Sunkara, Nishant N Gholap, Amar Vishal, Dev Manohar, Robin C Raju, Delayed treatment of paediatric supracondylar humerus fracture with neuro-vascular compromise. IJOMCR , International Journal Of Medical Case Reports | Jan-March 2023 | Volume 5 | Issue 1-2024 P14-18